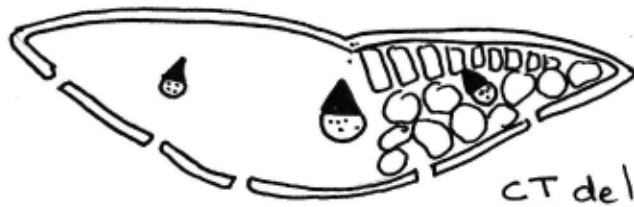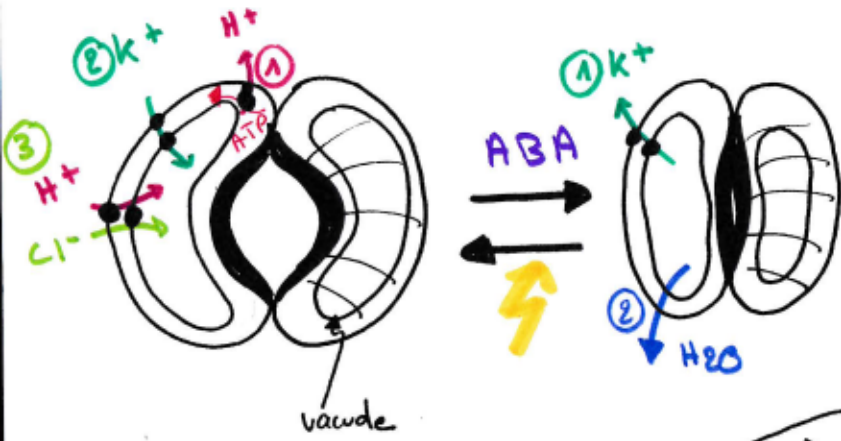


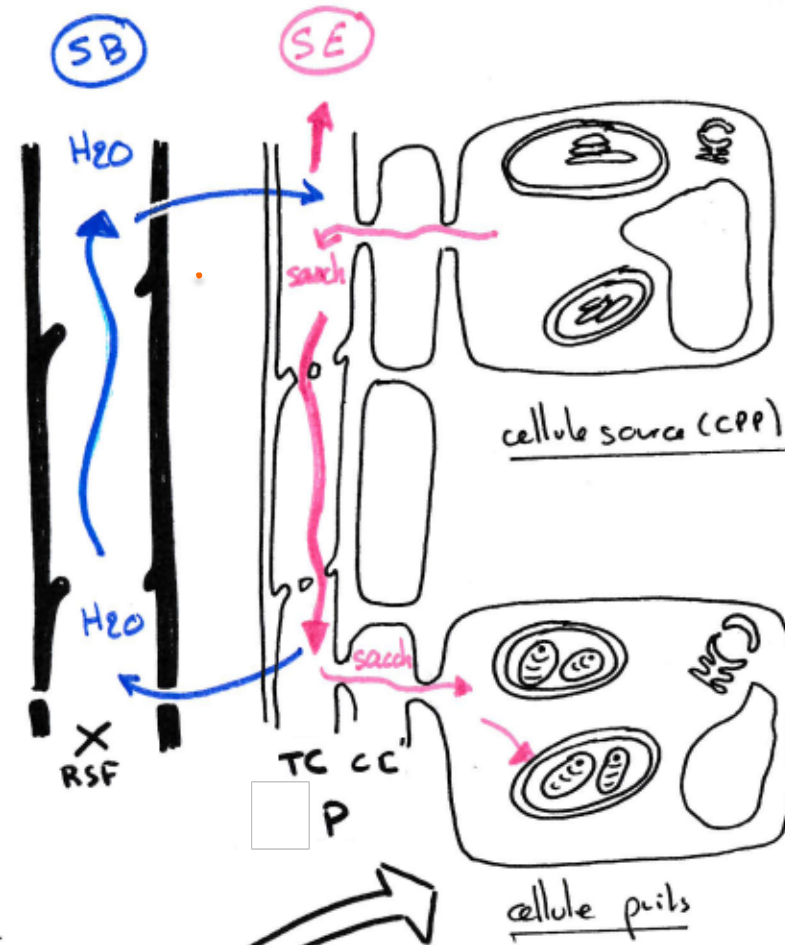
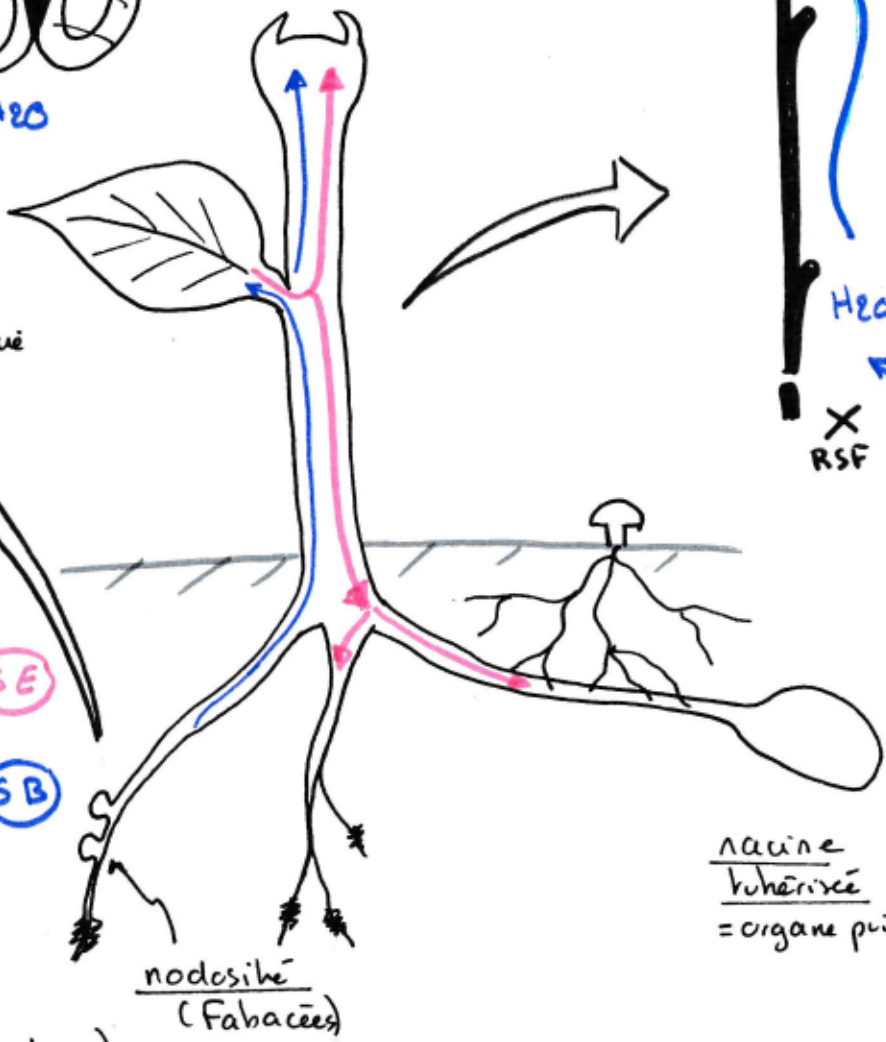
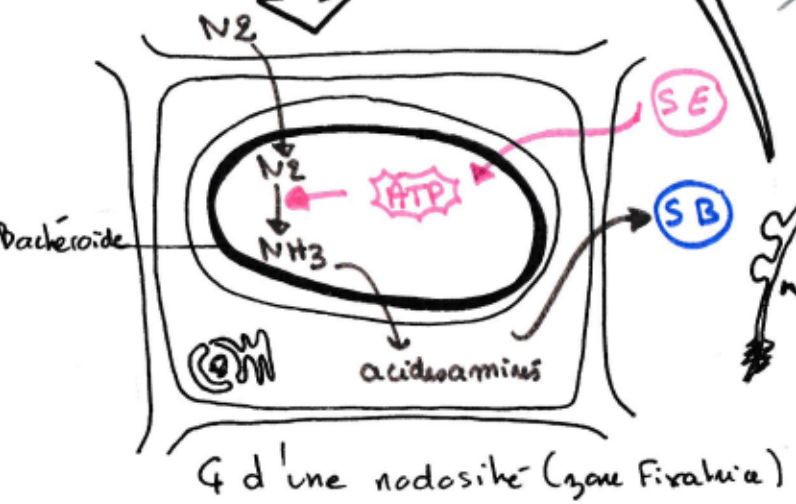
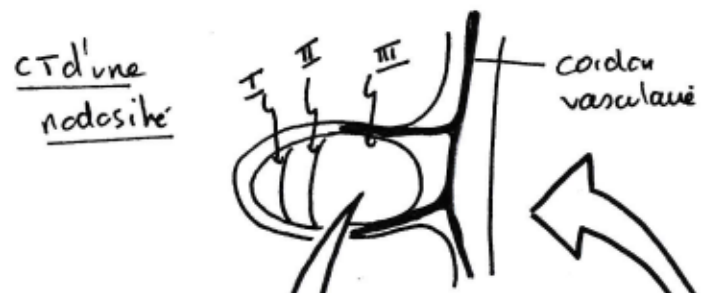
Distribution des photoassimilats et circulation des sèves



CT de limbe



CT d'une nodosité



racine tubérisée = organe puits.