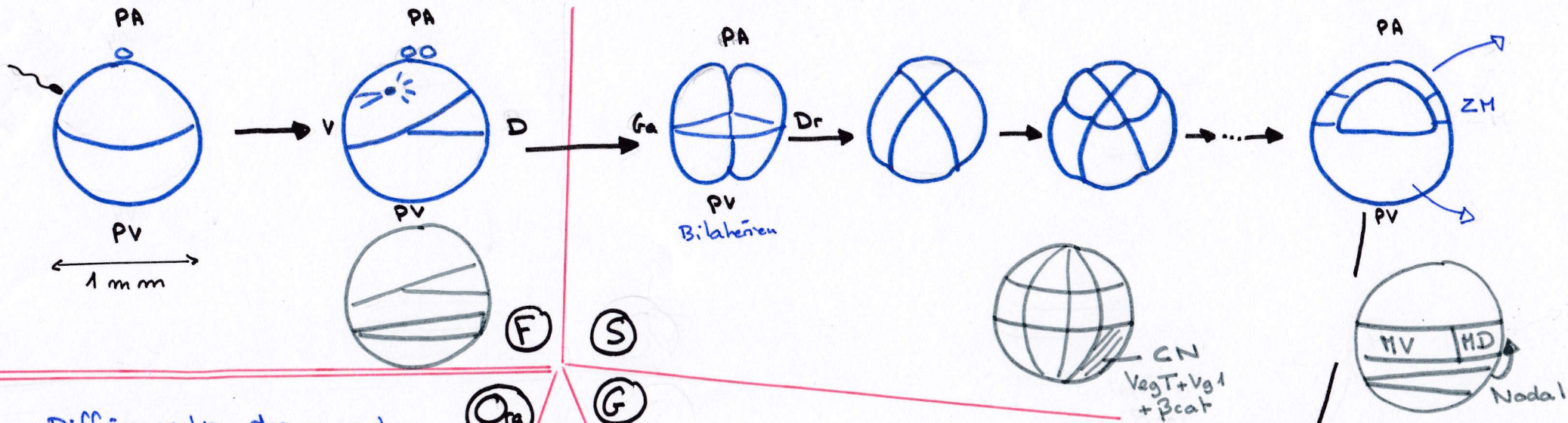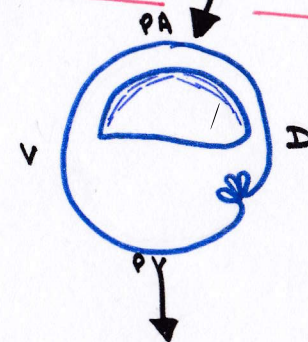
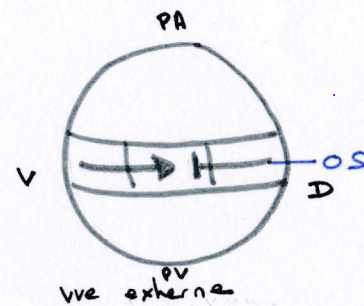

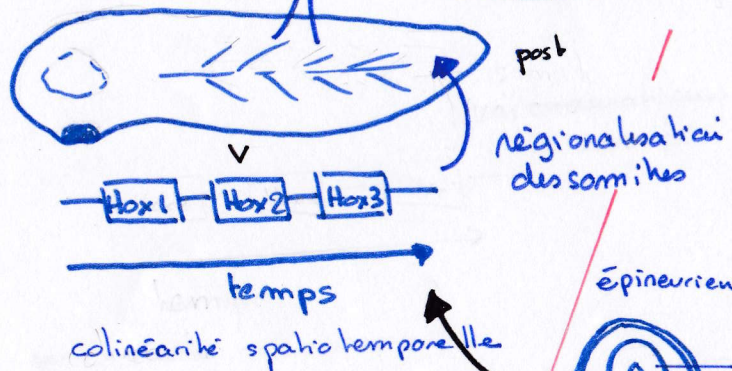
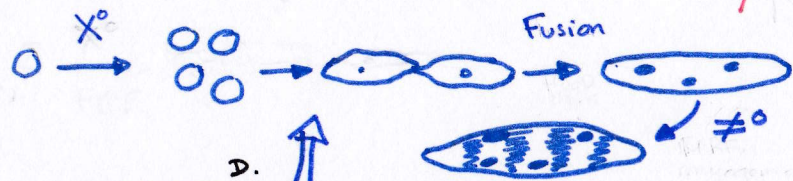
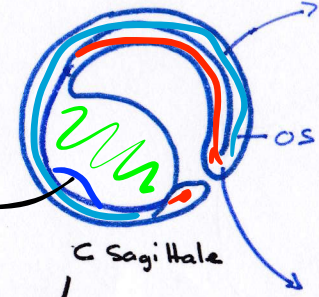


Différenciation des myocytes (myotome)



endoderme
=> internalisation
blastocèle



Ectoderme

=> épibolie

intercalation radiales

Mésoderme

=> extension CV
-> intercalation latérale

=> migration

